

The effect of hyperbaric oxygenation on the distal intestine of rats subjected to ionizing radiation

Rodrigo Ribeiro Aprilli, Rogério Serafim Parra, Harley Francisco de Oliveira, Francisco Aprilli, José Joaquim Ribeiro da Rocha, Omar Féres

Division of Coloproctology, Department of Surgery and Anatomy. School of Medicine of Ribeirão Preto, University of São Paulo

CORRESPONDING AUTHOR: Dr. Omar Féres – omar.feres@hspaulo.com.br

ABSTRACT

The current study was to test an experimental model of actinic lesions in the distal intestine of rats and to determine the possible protective effect of hyperbaric oxygen therapy (HBO₂) in radio-induced lesions when concomitantly applied with ionizing radiation. Twenty-four Wistar rats were divided into four groups:

- G1 (control group);
- G2 (animals irradiated);
- G3 (animals irradiated plus HBO₂);
- G4 (only HBO₂).

The animals were evaluated for 28 days after the end of treatment and then euthanized. The distal intestine was resected for macroscopic and microscopic evaluation and immunohistochemistry. The animals in the G3 group lost weight during the treatment; all of the animals in the G2 group presented macroscopic mucosal lesions up until 28 days; the animals in the other three groups did not present macroscopic lesions. Microscopic mucosal lesions were observed in the specimens of the animals treated with ionizing radiation; in the animals from the G3 and G4 groups the lesions were less intense. For the immunohistochemical analysis, we observed the specimens taken from G3 group animals had more CD34+ cells. The experimental model proved to be useful in causing radio-induced lesions, and concomitantly applied HBO₂ is capable of reducing late actinic lesions.

INTRODUCTION

During radiotherapy of some pelvic tumors, such as cervical, prostate and rectal, early and late side effects may compromise patients' quality of life [1]. Cystitis, proctitis and vulvovaginitis are some of the side effects, and bleeding, fibrosis and even necrosis of the irradiated tissue can occur, which is referred to as an actinic lesion. Thus, the care used to reduce those effects is very relevant with respect to its precise indication and use [2].

In recent decades, the use of radiotherapy for some rectal tumors has had a large impact by increasing the chance of preserving the anal sphincter and decreasing the number of amputation surgeries of the rectum [3]. However, despite new radiotherapeutic technologies, which reduce the irradiated field, the appearance of actinic proctitis has not been avoided [4].

While many studies have aimed at effectively treating actinic lesions, in practice, they are difficult to cure. Therefore, our research was centered on the search for the prevention of such injuries [5].

Substances capable of decreasing the adverse biological effects of radiation, radioprotectors, have been

identified. In experimental studies, it has been demonstrated that the best radioprotectors are those that have a dosage reduction factor of between 2 and 2.7 in death due to lesions in the bone marrow or intestine [6].

Hyperbaric oxygen therapy (HBO₂T) is a medical treatment method that uses the administration of 100% oxygen (O₂) at pressures greater than that of the atmosphere [7].

HBO₂T affects angiogenesis, stimulating microvascularization and neocollagenation. The action mechanism of HBO₂T is related to the facilitation of hydroxylation of proline. This results in the formation of an exuberant granulation tissue, which due to hypoxia, in the irradiated tissues [8].

Thus, HBO₂T is a therapeutic option with an efficacy has already been demonstrated in various studies as a radioprotective therapy. HBO₂T can decrease the late side effects of the radiotherapy without the undesirable effects of some medications and the comorbidities of a more aggressive treatment, such as amputation of the rectum [9].

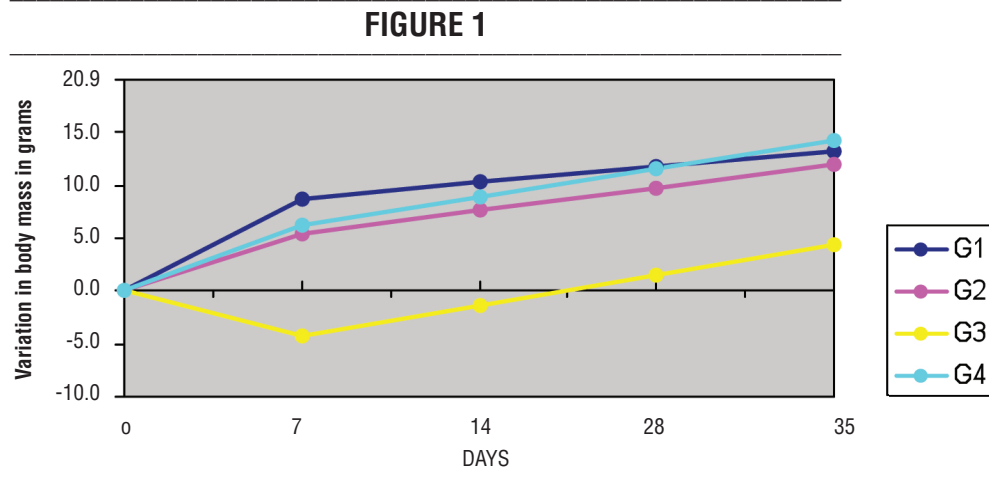


FIGURE 1: Average variation in body mass over 35 days.

With a better understanding of the physiotherapy of the actinic lesions, it seems logical to assume better tissue oxygenation during this form of treatment is a better alternative to minimize the deleterious effects of ionizing radiation [10].

The objective of the study was to test an experimental model of actinic lesions in the distal intestine of rats and to evaluate the effects of hyperbaric oxygenation applied concomitantly with ionizing radiation on radio-induced lesions in the distal intestines of rats.

METHODS

Twenty-four adult male Wistar rats (weighing between 250 and 350 g) were subjected to the same temperature, humidity and luminosity conditions and were fed with a standard diet.

After an adaptation period of one week, the animals were randomly distributed into four groups:

- **Control Group (G1):** Six animals that were not subjected to radiation or hyperbaric oxygenation;
- **Ionizing Radiation Group (G2):** Six animals irradiated with 42 Gy;
- **Ionizing Radiation and Hyperbaric Oxygenation Group (G3):** Six animals irradiated with 42 Gy and subjected to 90 minutes of hyperbaric oxygenation at 2 ATA; and
- **Hyperbaric Oxygenation Group (G4):** Six animals subjected to 90 minutes of hyperbaric oxygenation at 2 ATA.

To cause an actinic lesion in the distal intestine of the rats, the conventional limit for treatment of prostate cancer was used, which is 2 Gy daily for 38 days. To optimize the tissue damage, the biologically effective dose (BED) was calculated as described by Fowler

[11]: $BED = n.d. [1 + d/(\alpha/\beta)]$. Thus, the total radiation dose used was 42 Gy, which was fractionated into daily sessions of 7 Gy for six days. Radiation was administered with an interstitial brachytherapy probe adapted for intraluminal radiation that was positioned in the distal intestine of the rats 5 cm from the anal border.

Hyperbaric oxygenation was performed in a metal, cylindrical hyperbaric chamber for small-sized animals, which had a 10-L capacity with a continuous flow of 14 L/minute of 100% O₂. The chamber pressure was gradually increased for 15 minutes until reaching 2 ATA, after which it was stabilized over the next 90 minutes. In the final 15 minutes, the chamber was depressurized, for a total time of 120 minutes.

The animals were evaluated in relation to changes in body mass, which was measured after the one-week adaptation period, starting on the seventh and 35th days after the beginning of the treatment. Possible intestinal manifestations were also evaluated (diarrhea and bleeding) along with extraintestinal manifestations that may have been related to the treatment. One animal in the G3 group and one in the G4 group died; neither was substituted.

The surviving animals were subjected to euthanasia with an intracardiac injection of Thiopental anesthetic 28 days after the end of treatment protocol. The distal intestine of each animal was resected for subsequent macroscopic, microscopic and immunohistochemical studies.

RESULTS

One day after the end of the ionizing radiation, the rats of the G1, G2 and G4 groups gained an average of 8.8 g, 5.5 g and 6.3 g, respectively, and the rats of the G3 group lost an average of 4.2 g, shown in *Figure 1 (above)*.

FIGURE 2

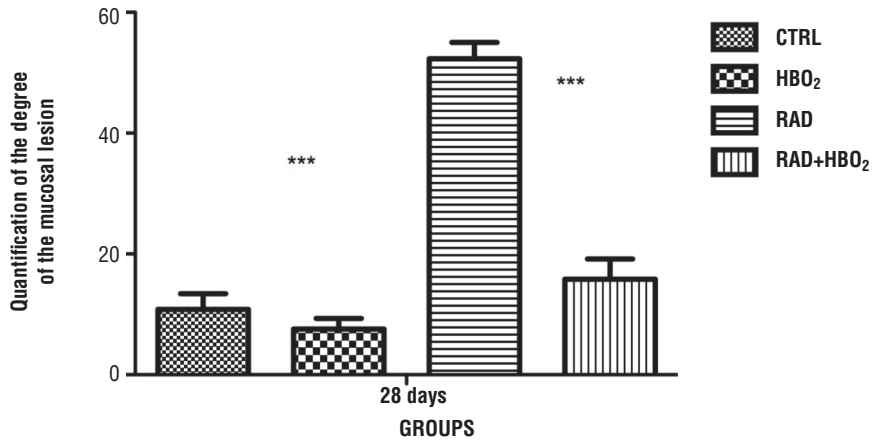


FIGURE 2: Destruction of the tunica mucosa, $p < 0.0001$

All animals that underwent radiotherapy in the G2 and G3 groups had diarrhea without blood. One animal in the G3 group showed hematuria, probably secondary to actinic cystitis.

Twenty-eight days after the end of ionizing radiation, the animals of the G1, G2, G3 and G4 groups gained an average of 3 g, 4.3 g, 4.1 g and 3.34 g, respectively, in relation to the body mass measured immediately after the end of the treatment.

In the macroscopic findings, four rats of the G3 group had pallor of the mucus, and two rats had hyperemia and focal areas of hemorrhage. In the animals of the other groups, macroscopic lesions were not observed.

The results based on the classification of Chiu *et al.* [12] showed the group of animals subjected to radiation (RAD) exhibited greater destruction of the tunica mucosa. The best results or preservation of tunica mucosa were found in the groups subjected to hyperbaric oxygenation (HBO₂T) and concomitant radiation (RAD+HBO₂T). A $p < 0.0001$ indicates there was a significant difference among groups, as shown in *Figure 2 (above)*.

The best results of the CD34+ were found in Group G3 (RAD+HBO₂T). A $p < 0.05$ indicates there was a statistically significant difference among the compared groups, as shown in *Figure 3 (below)*.

FIGURE 3

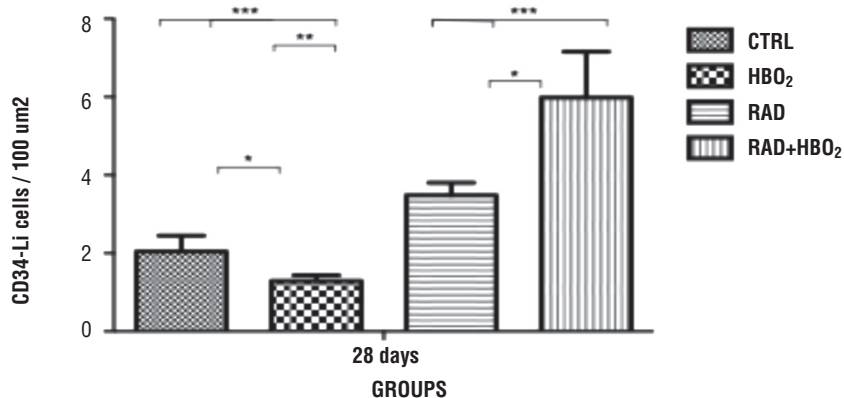


FIGURE 3: Expression of CD34+, $p < 0.05$

DISCUSSION

This work presents a model of actinic lesions in the distal intestine of rats associated with a therapeutic option (hyperbaric oxygenation), which may protect intestinal cells from the deleterious effects of radiation.

In the experimental model for production of actinic proctitis, an interstitial brachytherapy probe was used with six daily pulses of 7 Gy for a total of 42 Gy. An experimental study in rats has already demonstrated late actinic proctitis with a low brachytherapy dose of 6 Gy [13]. In another experimental study, rectal stenosis was induced by a dose of 36.5 Gy by using brachytherapy with Ir192 as a form of ionizing radiation [14]. With a proposed dose of 42 Gy in this study, we were able to simulate the situation that occurs in patients with pelvic tumors who need to be subjected to radiotherapy, which has a dosing tolerance of 45 Gy.

The manifestations of actinic proctitis began during radiation sessions and were most evident in the group subjected to radiation and hyperbaric oxygenation [G3]. Given these findings, this experimental model promoted a clinical picture of acute actinic proctitis, with diarrhea and weight loss as showed in Figure 1, which was enhanced by hyperbaric oxygenation.

Indeed, hyperbaric oxygenation enhanced the effectiveness of irradiation when it was performed concomitantly with the radiotherapy sessions [15]. The increase in the supply of normobaric oxygen increases the production of free radicals, mainly represented by hydroxyl (OH⁻), with exacerbation of the oxidative DNA lesions and aggravation of the cell death index [16]. However, hyperbaric oxygen acts as a modulator by increasing the action of the free radical “scanners” such as superoxide dismutase.

Hyperbaric oxygenation also promotes an increase in the production of nitric oxide with consequent local vasodilatation. This decreases ischemia in the acute phase of the ionizing application, which may be one of the mechanisms of decreasing apoptosis, making it a potentiating factor against radio-induced lesions [17].

Actinic lesions are ischemic, and to synthesize collagen, the fibroblasts need a tissue tension of 30 to 40 mmHg [18]; thus, hyperoxia allows for the stimulation of the fibroblast activity in the tissue, which is indispensable for neovascularization (19).

HBO₂T causes an increase in the rate of tissue oxygenation and is already used for identification of hypoxic tumors, which are subjected to radiotherapy for

potentiation of the treatment. Patients are subjected to 60 minutes of HBO₂T and 10-20 minutes of radiotherapy [20].

On the other hand, clinical studies have shown the beneficial effect of HBO₂T in the treatment of actinic proctitis [21]. In an experimental study of rats, Feldmeier *et al.* [10] evaluated the morphological and morphometric changes of late actinic lesions in the ileum of rats subjected to 30 sessions of HBO₂T seven weeks after the end of ionizing radiation. The authors confirmed its protective effect.

In another experimental study, Pereira *et al.* [22] evaluated the large intestine of rats subjected to five daily sessions of HBO₂T. Seven days after the end of ionizing radiation, they found HBO₂T decreases the morphological alterations of the mucosa and submucosa.

In the current study, HBO₂T with RAD was used. The animals were irradiated and then exposed to hyperbaric oxygenation, simulating a situation in which the patient is moved from his/her residence for treatment that occurs in a single visit.

Actinic lesions are by nature ischemic and are stimuli for neovascularization [8]. In addition, hyperoxia-hypoxia variation creates relative hypoxia, which is another stimulus of neovascularization [23].

Milovanova *et al.* [23] proposed if reactive oxygen species (trophic stimuli that are the progenitor of stem cells) are exposed by hyperbaric oxygenation, it would lead to an increase in the growth and differentiation of progenitor stem cells. Using an experimental model, they concluded hyperbaric oxygenation does indeed stimulate the growth and differentiation of the progenitor stem cells identified by the increase of CD34⁺.

In this study, CD34 expression was observed in the irradiated group (G2) and in the group subjected to HBO₂T (G4); however, the expression was greatest in the group that was both irradiated and subjected to HBO₂T sessions (G3). The interpretation of these data is that HBO₂T impedes the continuous deleterious effect of ionizing radiation, stimulating neovascularization from the moment treatment is initiated, thereby avoiding late actinic lesions. On the other hand, the supply of O₂ during ionizing radiation acutely enhances its effect, mainly due to the exacerbation of the indirect mechanism of ionizing radiation.

These results demonstrate the proposed model of actinic proctitis was appropriate for the study and may be used in other research protocols. Additionally, hyperbaric oxygenation proved to be beneficial for avoiding late actinic lesions.

We conclude that the experimental model was effective in causing actinic lesions in the distal intestine of rats. Hyperbaric oxygenation proved to be effective as a radioprotective agent because it minimized late actinic lesions in the distal intestine of rats, which was demonstrated by less evident macroscopic lesions, less intense microscopic lesions, and an increase in the number of stem cells (CD34+).



REFERENCES

1. Johnson RJ, Carrington BM. Pelvic radiation disease. *Clin Radiol*. 1992 Jan;45(1):4-12.
2. Lichter AS, Lawrence TS. Recent advances in radiation oncology. *N Engl J Med*. 1995 Feb 9;332(6):371-9.
3. Williams NS. Radiotherapy and chemotherapy for primary colorectal cancer, supervision and recurrence. In: Keighley MRB, Williams NS, eds. *Surgery of the anus, rectum, and colon*. 1st ed. São Paulo: Malone Ltda, 1988:1002-37.
4. Zimmermann FB, Feldmann HJ. Radiation proctitis. Clinical and pathological manifestations, therapy and prophylaxis of acute and late injurious effects of radiation on the rectal mucosa. *Strahlenther Onkol*. 1998 Nov;174 Suppl 3:85-9.
5. Montana GS, Anscher MS, Mansbach CM 2nd, Daly N, Delannes M, Carke-Pearson D, et al. Topical application of WR-2721 to prevent radiation-induced proctosigmoiditis. A phase I/II trial. *Cancer*. 1992 Jun 1;69(11):2826-30.
6. Segreto HRC, Segreto RA. Review and updates in radiobiology. Cellular, molecular, and clinical aspects. *Folha Méd* 2000; 119:9-27.
7. Valiñas LP. New technologies, rediscovering hyperbaric oxygenation. *Rev Galega Actual Sanit* 2003; 2:318-22.
8. Feldmeier JJ, Hampson NB. A systematic review of the literature reporting the application of hyperbaric oxygen prevention and treatment of delayed radiation injuries: an evidence based approach. *Undersea Hyperb Med*. 2002 Spring;29(1):4-30.
9. Abbasakoor F, Vaizey CJ, Boulos PB. Improving the morbidity of anorectal injury from pelvic radiotherapy. *Colorectal Dis*. 2006 Jan;8(1):2-10.
10. Feldmeier JJ, Davolt DA, Court WS, Onoda JM, Alecu R. Histologic morphometry confirms a prophylactic effect for hyperbaric oxygen in the prevention of delayed radiation enteropathy. *Undersea Hyperb Med*. 1998 Summer;25(2):93-7.
11. Fowler JF. The linear-quadratic formula and progress in fractionated radiotherapy. *Br J Radiol*. 1989 Aug;62(740):679-94.
12. Chiu CJ, McArdle AH, Brown R, Scott HJ, Gurd FN. Intestinal mucosal lesion in low-flow states. I. A morphological, hemodynamic, and metabolic reappraisal. *Arch Surg*. 1970 Oct;101(4):478-83.
13. Armour EP, White JR, Armin A, Corry PM, Coffey M, DeWitt C, Martinez A. Pulsed low dose rate brachytherapy in a rat model: dependence of late rectal injury on radiation pulse size. *Int J Radiat Oncol Biol Phys*. 1997 Jul 1;38(4):825-34.
14. Johannessen HO, Dale E, Hellebust TP, Olsen DR, Nesland JM, Giercksky KE. Modeling volume effects of experimental brachytherapy in the rat rectum: uncovering the limitations of a radiobiologic concept. *Int J Radiat Oncol Biol Phys*. 2002 Jul 15;53(4):1014-22.
15. Salvaioli J, Souhami L, Faria S. *Radiation Oncology*. 1st ed. São Paulo: Editora Médica e Científica Ltda, 1999.
16. Bersimbaev RI, Yugai YE, Hanson PJ, Tzoy IG. Effect of nitric oxide on apoptotic activity in the rat gastrointestinal tract. *Eur J Pharmacol*. 2001 Jun 29;423(1):9-16.
17. Kindwall EP. Hyperbaric oxygen treatment of radiation cystitis. *Clin Plast Surg*. 1993 Jul;20(3):589-92.
18. Roh JL. Chondroradionecrosis of the larynx: diagnostic and therapeutic measures for saving the organ from radiotherapy sequelae. *Clin Exp Otorhinolaryngol*. 2009 Sep;2(3):115-9.
19. Kaur J, Hay KD, Macdonald H, Rich AM. Retrospective audit of the use of the Marx Protocol for prophylactic hyperbaric oxygen therapy in managing patients requiring dental extractions following radiotherapy to the head and neck. *N Z Dent J*. 2009 Jun;105(2):47-50.
20. Mayer R, Hamilton-Farrell MR, van der Kleij AJ, Schmutz J, Granström G, Sicko Z. Hyperbaric oxygen and radiotherapy. *Strahlenther Onkol*. 2005 Feb;181(2):113-23.
21. Woo TC, Joseph D, Oxer H. Hyperbaric oxygen treatment for radiation proctitis. *Int J Radiat Oncol Biol Phys*. 1997 Jun 1;38(3):619-22.
22. Pereira MLL, Scheidt TC, Simões MdJ, Mosquette R, Gomes PdO. Oxigenoterapia hiperbárica em lesões actínicas de colo de ratos: aspectos morfológicos e morfométricos. *Acta Cir Bras* 2004; 19:658-63.
23. Milovanova TN, Bhopale VM, Sorokina EM, Moore JS, Hunt TK, Hauer-Jensen M, et al. Hyperbaric oxygen stimulates vasculogenic stem cell growth and differentiation in vivo. *J Appl Physiol*. 2009 Feb;106(2):711-28. Epub 2008 Nov 20.

